Accuracy of Point-of-Care Ultrasonography for Diagnosis of Elbow Fractures in Children

Joni E. Rabiner, MD, Hnin Khine, MD, Jeffrey R. Avner, MD, Lana M. Friedman, MD, James W. Tsung, MD, MPH

From the Department of Pediatrics, Division of Pediatric Emergency Medicine, Children's Hospital at Montefiore/Albert Einstein College of Medicine, Bronx, NY (Rabiner, Khine, Avner); and the Department of Emergency Medicine, Division of Pediatric Emergency Medicine, Mount Sinai Medical Center/Mount Sinai School of Medicine, New York, NY (Friedman, Tsung).

Study objective: We determine the test performance characteristics for point-of-care ultrasonography performed by pediatric emergency physicians compared with radiographic diagnosis of elbow fractures and compare interobserver agreement between enrolling physicians and an experienced pediatric emergency medicine sonologist.

Methods: This was a prospective study of children aged up to 21 years and presenting to the emergency department (ED) with elbow injuries requiring radiographs. Before obtaining radiographs, pediatric emergency physicians performed focused elbow ultrasonography. An ultrasonographic result positive for fracture at the elbow was defined as the pediatric emergency physician's determination of an elevated posterior fat pad or lipohemarthrosis of the posterior fat pad. All patients received an elbow radiograph in the ED and clinical follow-up. The criterion standard for fracture was fracture on initial or follow-up radiographs.

Results: One hundred thirty patients with a mean age of 7.5 years were enrolled by 26 sonologists. Forty-three (33%) patients had a radiograph result positive for fracture. A positive elbow ultrasonographic result had a sensitivity of 98% (95% confidence interval [CI] 88% to 100%), specificity of 70% (95% CI 60% to 79%), positive likelihood ratio of 3.3 (95% CI 2.4 to 4.5), and negative likelihood ratio of 0.03 (95% CI 0.01 to 0.23) for fracture. The interobserver agreement (κ) was 0.77. The use of elbow ultrasonography would reduce radiographs in 48% of patients but would miss 1 fracture.

Conclusion: Point-of-care ultrasonography is highly sensitive for elbow fractures, and a negative ultrasonographic result may reduce the need for radiographs in children with elbow injuries. Elbow ultrasonography may be useful in settings in which radiography is not readily accessible or is time consuming to obtain. [Ann Emerg Med. 2012;xx:xxx.]

Please see page XX for the Editor's Capsule Summary of this article.

0196-0644/$-see front matter

http://dx.doi.org/10.1016/j.annemergmed.2012.07.112

INTRODUCTION

Background

Elbow injuries are a common presenting complaint to the pediatric emergency department (ED), and radiographic imaging is often obtained for evaluation of suspected fracture. Elbow fractures account for up to 15% of fractures in children.[1,2] The posterior fat pad sign on radiography is elevation of the intracapsular, extrasynovial posterior fat pad that normally lies in the olecranon fossa because of elbow joint effusion. In the setting of elbow trauma, it has been shown to be highly sensitive for fracture.[3-7]

Ultrasonography is an imaging modality that can be performed accurately and reliably by emergency physicians with limited, focused training.[8,9] Recent studies have shown the utility of musculoskeletal ultrasonography in diagnosing adult[10,11] and pediatric fractures[12-18] by direct identification of cortical disruption. In these studies, it has been shown that there is greater accuracy for fracture detection in the midshaft of long bones and that fractures adjacent to joint spaces, small avulsion injuries, Salter-Harris type 1 fractures, fractures involving the small bones of the hands and feet, and fractures smaller than 1 mm may be missed on ultrasonography.[12–18] Ultrasonography has many advantages over other imaging modalities, including lack of radiation, speed, portability, cost-effectiveness, and ease of use, and has been cited as "an ideal diagnostic tool for children."[19] In addition, it has been shown in multiple studies to be well tolerated by children in the evaluation of injury.[11-13,17,18]

In children, it may be technically difficult to directly visualize fractures at the elbow joint with ultrasonography because of variation in the ossification centers and the multiple curved contours at the ends of the distal humerus, proximal radius, and proximal ulna. However, an elevated posterior fat pad can be easily visualized on ultrasonography, it may be a reliable sign for

Editor's Capsule Summary

What is already known on this topic

Point-of-care ultrasonography is useful in diagnosing long bone fractures. It is unknown whether ultrasonography is helpful in diagnosing pediatric elbow fractures.

What question this study addressed

Novice emergency physicians with limited, focused ultrasonographic training prospectively performed point-of-care ultrasonography to identify elevated posterior fat pad or lipohemarthrosis in 130 children aged 0 to 21 years and undergoing radiography for elbow injury. Radiography result was positive for fracture in 33%; ultrasonography had a sensitivity of 98% and specificity of 70%.

What this study adds to our knowledge

Ultrasonography may be useful to rule out elbow fracture.

How this is relevant to clinical practice

Clinicians in austere settings or outpatient facilities without easy access to radiography may find ultrasonography useful to screen patients for elbow fracture.

fracture, and ultrasonography has been shown to be more sensitive than radiography in detecting posterior fat pad elevation.[20-22] Articular fractures involving the distal humerus, including supracondylar and lateral condylar fractures, or proximal ulna or radius produce a joint effusion leading to an elevated posterior fat pad.[1,23] However, elbow joint effusion after trauma is not always associated with a cortical fracture, and the additional finding of lipohemarthrosis may help differentiate fractures at the elbow.[24] In the setting of trauma, lipohemarthrosis represents blood and lipid material in the posterior fat pad, which often accompanies an elbow fracture.

Goals of This Investigation

Our objective was to determine the test performance characteristics for point-of-care ultrasonography performed by pediatric emergency physicians compared with radiography for the diagnosis of elbow fractures in children. Our secondary objective was to compare interobserver agreement between enrolling pediatric emergency physicians and an experienced pediatric emergency medicine sonologist.

MATERIALS AND METHODS

Study Design and Setting

This was a prospective, observational study conducted from September 1, 2010, to December 31, 2011, in 2 urban pediatric EDs. A convenience sample of patients with elbow injuries requiring radiographic evaluation for fracture, presenting when a trained study physician was available, was eligible for enrollment into the study. Written informed consent was obtained from the patient or parent or guardian, and written assent was obtained from patients aged 7 years or older. Approval for this study was granted by the hospitals' institutional review boards.

Selection of Participants

Inclusion criteria included patient's age up to 21 years, with a possible elbow fracture requiring radiographic evaluation, as determined by the attending pediatric emergency physician. Patients were excluded if they arrived at the ED with a radiograph of the injured elbow already performed, a previously confirmed diagnosis of elbow fracture, an open wound at the elbow, or unstable vital signs or associated life-threatening injuries requiring resuscitation.

Methods of Measurement

Before the start of the study, all participating pediatric emergency medicine attending physicians and fellows attended a 30-minute didactic session to teach the basics of how to use ultrasonography to evaluate the elbow for fracture and to standardize the method in which bedside ultrasonography was performed by physicians, followed by a 30-minute hands-on practical session with live models. A reference manual complete with instructions and images was available throughout the study.

Before performing the point-of-care ultrasonography, pediatric emergency physicians completed a data collection sheet and recorded physical examination findings (point tenderness, swelling, ecchymosis, deformity, decreased range of motion, or neurovascular compromise). The pediatric emergency physician also determined and recorded the clinical likelihood of elbow fracture before the ultrasonography (≤1%, 2% to 25%, 26% to 50%, 51% to 75%, 76% to 98%, or ≥99%).

Using either a SonoSite M-turbo or MicroMaxx ultrasonographic machine (SonoSite Inc., Bothell, WA) with a 5- to 10-MHz linear transducer probe, focused ultrasonography was performed by the pediatric emergency physician. With the patient's elbow flexed to 90 degrees,[20-22] the gel on the ultrasonographic probe was placed over the posterior aspect of the distal humerus to obtain images, with the probe in contact with the gel but not the underlying skin. Both longitudinal and transverse views of the elbow were obtained (Figure 1), and still pictures and video clips in each orientation were recorded. Ultrasonographic imaging of the contralateral normal, uninjured side was performed as needed for comparison.

A positive elbow ultrasonographic result was defined as the enrolling pediatric emergency physician's determination of elevation of the posterior fat pad or presence of lipohemarthrosis of the posterior fat pad. Elevation of the posterior fat pad was defined as rise of the fat pad above the extension of the distal

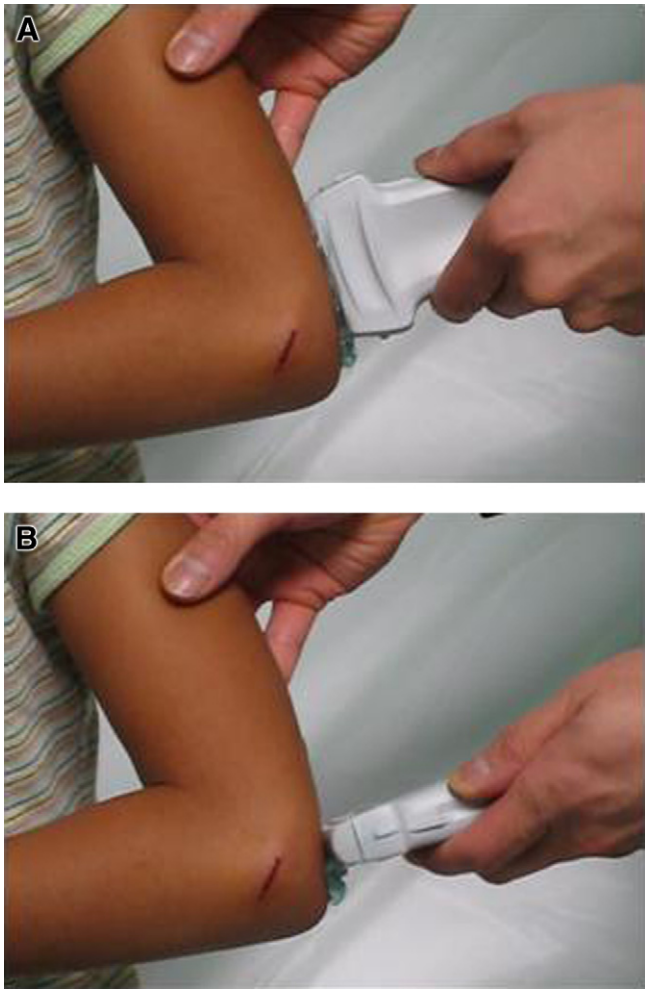

Figure 1. Elbow ultrasonography: longitudinal probe placement (*A*) and transverse probe placement (*B*).

humeral line on longitudinal view or above a line connecting both lips of the olecranon fossa on transverse view (Figure 2). Lipohemarthrosis was defined as heterogeneous echodensity with hypoechoic areas of the posterior fat pad (Figure 3). The enrolling physician recorded the ultrasonographic findings on data collection forms immediately after the procedure and before reviewing any radiographic imaging studies. All test-performance characteristics were analyzed according to the enrolling pediatric emergency physician's determination of posterior fat pad elevation or lipohemarthrosis.

To provide a measure of agreement with an expert, the recorded still photos and video clips were later reviewed by an experienced pediatric emergency medicine sonologist (J.W.T.) with more than 10 years of point-of-care ultrasonographic clinical and teaching experience and who was blinded to clinical findings, the enrolling physician's ultrasonographic interpretation, and radiographic imaging. In addition, the time to perform the point-of-care ultrasonography was determined from the time stamps on the first and last ultrasonographic images recorded for each patient.

After completion of the point-of-care ultrasonography, all patients had radiography as per the standard of care evaluation. Fracture on radiograph was defined as "cortical irregularity" or "fracture" on the attending radiologist's report, which served as the criterion standard for fracture. Attending radiologists were blinded to the ultrasonographic results.

For patients without definite fracture on initial radiography in the ED, clinical follow-up consisted of review of electronic medical records or structured clinical telephone follow-up to ascertain final outcomes (fracture or no fracture). On follow-up imaging, a diagnosis of fracture was made if there was reporting of "cortical irregularity," "fracture," or "healing fracture" by the attending radiologist. In patients for whom no follow-up imaging was performed, the clinical diagnosis of no fracture was confirmed by resolution of all clinical symptoms on structured clinical telephone follow-up at least 1 week after the initial ED visit. A positive fracture result in this study was a fracture diagnosed at initial presentation or a fracture diagnosed on follow-up imaging.

To allow comparison of posterior fat pad elevation on ultrasonography to radiograph, the test performance characteristics for posterior fat pad elevation on radiograph were also calculated for elbow fracture.

Outcome Measures

Our primary outcome was to determine the test performance characteristics of an elevated posterior fat pad or the presence of lipohemarthrosis on point-of-care ultrasonography performed and interpreted by pediatric emergency physicians compared with the diagnosis of fracture based on radiographic imaging with clinical follow-up. Our secondary objective was to compare interobserver agreement between enrolling physicians and an experienced pediatric emergency medicine sonologist.

Primary Data Analysis

Data were analyzed with SPSS Statistics (IBM, Armonk, NY) and are described using sensitivity, specificity, positive and negative predictive values, positive and negative likelihood ratios, and 95% confidence intervals (CIs). Descriptive statistical analyses were used for categorical data. κ values were used to describe interobserver agreement.

Ignoring clustering by ultrasonographic operator and using the method of Arkin and Wachtel,[25] a sample size of 112 patients would be needed to obtain a 95% CI (SD 5%) around a 92% sensitivity or specificity for ultrasonographic diagnosis of elbow fractures according to the study by Weinberg et al.[17]

RESULTS

Characteristics of Study Subjects

One hundred thirty patients were enrolled, with a mean age of 7.5 years (SD 5.4 years; range 3 months to 21 years). The patients' demographic and clinical information is presented in Table 1. The study flow chart is presented in Figure 4. Four

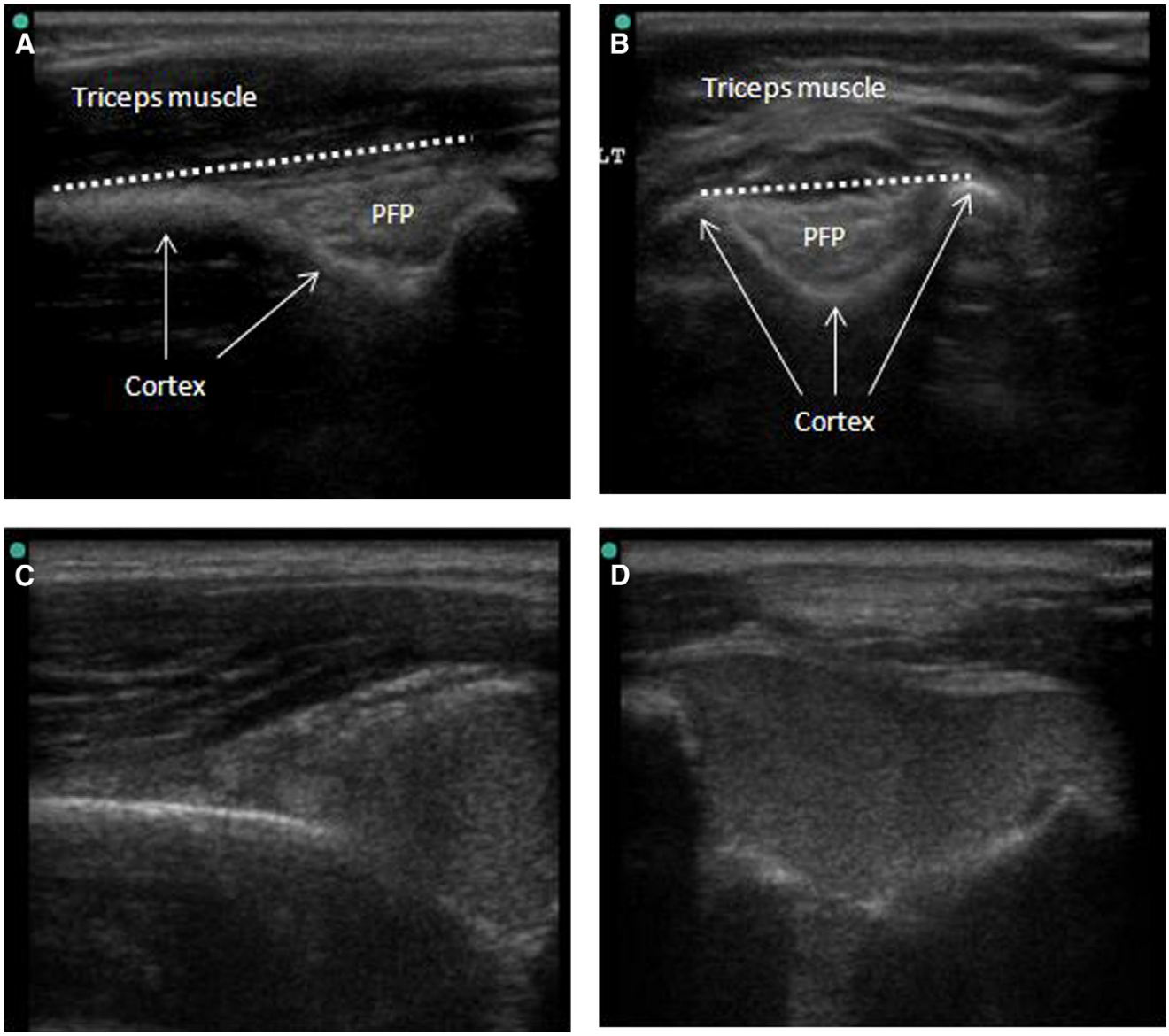

Figure 2. Normal posterior fat pad (PFP) in longitudinal view with the PFP below the distal humeral line (*A*) and transverse view with the PFP below the line connecting both lips of the olecranon fossa (*B*). Elevated PFP in longitudinal view (*C*) and transverse view (*D*).

patients (3%) did not have follow-up after the initial ED visit, and all 4 of these patients had a negative ultrasonographic result and a negative initial ED radiograph result for fracture and elbow effusion; these patients were included in the analysis as fracture absent.

Main Results

On initial ED radiography, fracture was present in 38 of 130 (29%) patients. On follow-up, of the 92 patients who did not have a fracture on initial radiography, 23 (25%) patients had repeated radiographs and 5 additional fractures were diagnosed. In total, fracture was present in 43 (33%) patients. The majority of elbow fractures were located in the distal humerus (n=37; 86%), with 23 (53%) supracondylar fractures, 9 (21%) lateral condyle/epicondyle fractures, and 5 (12%) medial epicondyle fractures; the remaining fractures involved the proximal ulna (n=4; 9%) and proximal radius (n=2; 5%).

An elevated posterior fat pad was present on initial radiograph in 57 of 130 (44%) patients, 36 with fracture and 21 without fracture at that time. Two patients with fracture in the ED did not have an elevated posterior fat pad on radiograph; 1 patient had a medial epicondyle fracture, and 1 patient had a proximal ulna fracture. Of the 21 patients who had an elevated posterior fat pad without fracture on initial ED radiography, 4 patients (19%) had fractures identified on follow-up (3 supracondylar fractures and 1 proximal ulna

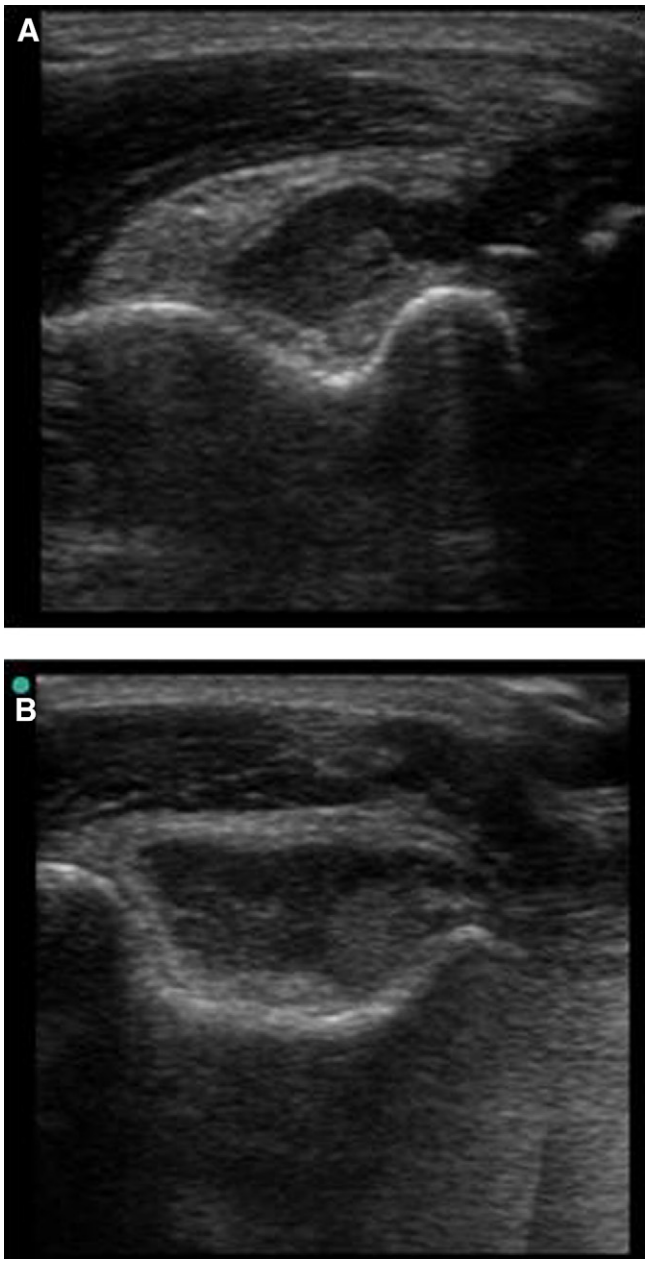

Figure 3. Elevated PFP with lipohemarthrosis (heterogenous echodensity) in longitudinal view (*A*) and transverse view (*B*).

Table 1. Patient demographics and clinical characteristics (N=130).

Demographics and Clinical Characteristics	No Fracture, No. (%) (n=87)	Fracture, No. (%) (n=43)
Sex		
Male	44 (51)	28 (65)
Female	43 (49)	15 (35)
Physical examination characteristics		
Point tenderness	61 (70)	39 (91)
Swelling	32 (37)	39 (91)
Ecchymosis	3 (3)	1 (2)
Deformity	4 (5)	11 (26)
Decreased range of motion	58 (67)	37 (86)
Neurovascular compromise	0	0
Pretest clinical assessment of fracture, %		
≤1	14 (16)	0
2–25	48 (55)	5 (12)
26–50	9 (10)	7 (16)
51–75	11 (13)	8 (19)
76–98	4 (5)	12 (28)
≥99	1 (1)	11 (26)

fracture). In addition, there was 1 lateral condyle fracture that was identified on follow-up imaging for a patient whose initial radiograph result was negative for fracture or elevated posterior fat pad. Elevated posterior fat pad on initial radiography had a sensitivity of 93% (95% CI 81% to 98%) and specificity of 79% (95% CI 70% to 87%) for fracture at the elbow.

On point-of-care ultrasonography, 68 of 130 patients (52%) had an elevated posterior fat pad or lipohemarthrosis as interpreted by the enrolling physician. Of these 68 patients, 61 (90%) had an elevated posterior fat pad, 57 (84%) had lipohemarthrosis, and 50 (74%) had both elevated posterior fat pad and lipohemarthrosis. According to a diagnosis of fracture by initial ED radiography and radiographic or clinical follow-up as the reference standard, the test performance characteristics for point-of-care ultrasonography of the elbow with 95% CI and κ values for agreement between the enrolling physicians and an experienced pediatric emergency medicine sonologist are presented in Table 2. The diagnostic test results for each point-of-care ultrasonograph performed compared with the reference standard and the agreement between enrolling pediatric emergency physicians and the expert pediatric emergency medicine sonologist for each point-of-care ultrasonograph is shown in Figure 5. Elbow ultrasonographic scans took a median of 95 seconds (interquartile range 63 to 166 seconds) to perform in the ED.

There were 15 patients with deformity at the elbow on physical examination, and of these, 11 (73%) had fracture on radiograph (Table 1). For the patients with deformity present, the sensitivity and specificity of elbow ultrasonography for fracture at the elbow was 100%. For those without deformity present (n=115), the sensitivity of elbow ultrasonography was 0.97 (95% CI 0.84 to 0.99) and the specificity was 0.69 (95% CI 0.58 to 0.78).

Twenty-six enrolling physicians performed elbow ultrasonography, with a mean of 5.0 scans (SD 5.5 scans; range 1 to 24 scans) and a median of 3 scans each (interquartile range 1 to 6 scans). Only 1 sonologist, who enrolled 12 patients into this study, had experience in elbow ultrasonography before the start of the study. For the first quartile of patients enrolled (n=32), the κ for interobserver agreement between enrolling

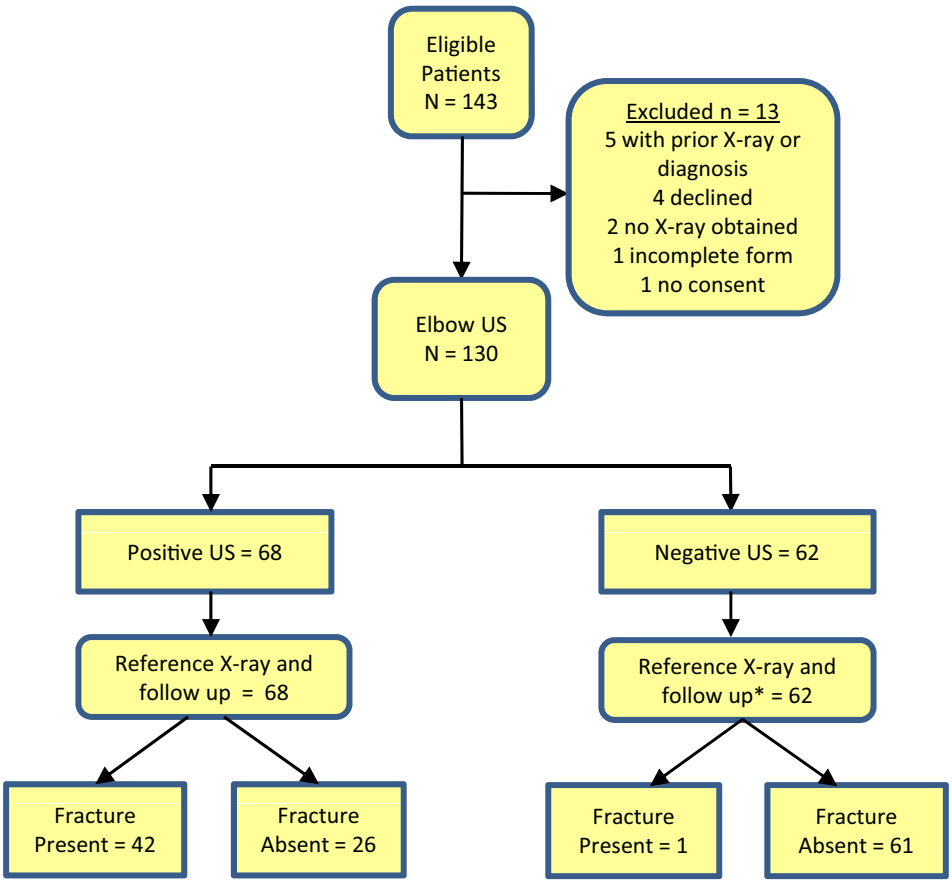

Figure 4. Study flow chart. *Four patients with no follow-up had negative elbow ultrasonographs and negative radiographs at the index ED visit and are analyzed in the Fracture Absent group.

Table 2. Test performance characteristics for point-of-care ultrasonographic diagnosis of elbow fractures (N=130).

Ultrasonographic Findings	Sensitivity (%)	Specificity (%)	PPV	NPV	LR+	LR−	κ
	95% CI						
Elevated PFP or LH	98 (88–100)	70 (60–79)	0.62 (0.50–0.72)	0.98 (0.91–1.0)	3.3 (2.4–4.5)	0.03 (0.01–0.23)	0.77 (0.66–0.88)
Elevated PFP	93 (81–98)	76 (66–84)	0.66 (0.53–0.76)	0.96 (0.88–0.99)	3.9 (2.6–5.6)	0.09 (0.03–0.28)	0.78 (0.68–0.89)
LH	91 (78–96)	79 (70–87)	0.68 (0.56–0.79)	0.95 (0.87–0.98)	4.4 (2.9–6.7)	0.12 (0.05–0.30)	0.72 (0.60–0.84)
Elevated PFP and LH	86 (73–93)	85 (76–91)	0.74 (0.60–0.84)	0.93 (0.85–0.97)	5.8 (3.4–9.6)	0.16 (0.08–0.35)	0.73 (0.62–0.85)

PPV, Positive predictive value; *NPV*, negative predictive value; *LR+*, likelihood ratio for a positive test; *LR–*, likelihood ratio for a negative test; *LH*, lipohemarthrosis.

pediatric emergency physicians and the expert pediatric emergency medicine sonologist for point-of-care ultrasonography (positive versus negative) was 0.74 (95% CI 0.51 to 0.98), with 4 operator interpretation errors distributed among 3 sonologists. For the last quartile of patients enrolled (n=32), the κ was 0.94 (95% CI 0.82 to 1.0), with 1 discordant ultrasonographic interpretation.

There was only 1 instance of fracture with a normal posterior fat pad and absence of lipohemarthrosis on point-of-care ultrasonography. In this case, the pretest clinical assessment of fracture was 2% to 25%, and there was agreement in the ultrasonographic interpretation between the enrolling sonologist and the expert reviewer. This missed fracture was in a 9-year-old patient whose initial radiograph showed no visible posterior fat pad but was suggestive of a Salter-Harris type 1 fracture of the medial epicondyle. This patient had a subsequent elbow computed tomography scan, which showed a Salter-Harris type 2 avulsion fracture of the medial epicondyle with an elevated posterior fat pad. This child was managed nonoperatively with splinting, and repeated imaging showed a healing fracture.

In addition, there was 1 patient who had a positive ultrasonographic result, as interpreted by both the enrolling physician and the expert sonologist, and had initial ED radiography that was negative for fracture or elevated posterior fat pad and was found to have a lateral condyle fracture on

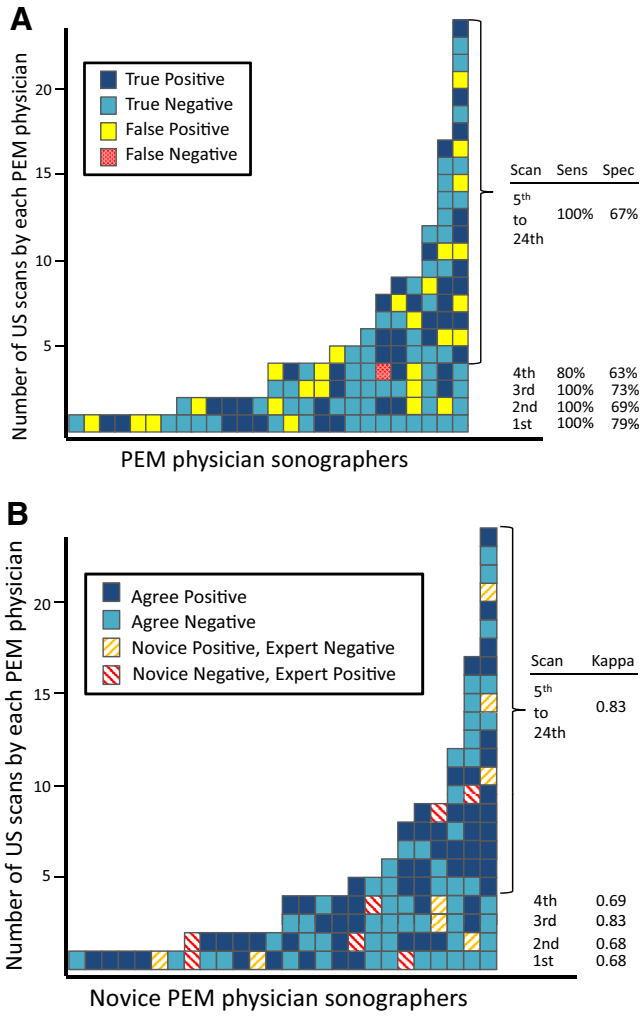

Figure 5. Diagnostic results for each point-of-care ultrasonographic study performed by a pediatric emergency physician compared with the reference standard of initial ED radiography and radiographic or clinical follow-up (*A*) and agreement between enrolling pediatric emergency physicians and an experienced pediatric emergency medicine sonologist for each point-of-care ultrasonographic study performed (*B*). Each block represents a unique patient enrolled by a pediatric emergency physician sonologist (*x* axis), with the number of ultrasonographic scans performed by each pediatric emergency physician (*y* axis), and each block is color coded to show the test result compared with the reference standard (*A*) or the agreement with the expert sonologist (*B*). The blocks are arranged vertically in chronological order, with the first ultrasonographic scan at the bottom. The sensitivity and specificity (*A*) and κ values for interobserver agreement (*B*) for point-of-care elbow ultrasonography are given for the first, second, third, fourth, and fifth to 24th ultrasonographic scans performed by physicians.

repeated radiography. A posterior arm splint was applied in the ED for significant tenderness to palpation, swelling, and decreased range of motion on physical examination, and the fracture was observed on follow-up imaging.

The use of point-of-care ultrasonography of the elbow would reduce the need for radiography in 62 of 130 (48%) patients with elbow injuries but would miss 1 fracture in children aged 3 months to 21 years and presenting to the ED after elbow trauma.

LIMITATIONS

Our study had a few limitations. It included a convenience sample of patients enrolled when a trained physician was available, but we believe that our sample is a generalizable group of patients, given the similar distribution of elbow fractures compared with that of other larger published studies.[23,26,27] In addition, we conducted the study during 16 months to avoid any seasonal variations. Another limitation of the study was that not all patients received repeated radiography to confirm or refute the presence of a fracture because it was not practical or ethical to repeat radiography on all patients if it was not clinically indicated. However, we made follow-up telephone calls or reviewed electronic medical records to confirm that the patient's clinical status was consistent with the diagnosis. Furthermore, ultrasonography is an operator-dependent modality, but we used a group of novice sonologists and our results may be generalizable to other clinicians with focused ultrasonographic training. Last, the findings from our study apply only to patients with isolated elbow injuries. Patients with additional injuries involving the forearm or wrist may require other imaging studies.

DISCUSSION

Elbow injuries are a common occurrence in pediatrics. We have shown that point-of-care sonographic identification of an elevated posterior fat pad and lipohemarthrosis is a feasible, accurate, and reliable marker for elbow fractures. Point-of-care elbow ultrasonography may help to distinguish patients who are at risk for elbow fracture and need further radiographic evaluation.

Our study examined posterior fat pad elevation and lipohemarthrosis as signs for fracture at the elbow. This is in contrast to most other musculoskeletal ultrasonographic studies that have sought to directly visualize a cortical disruption as an indication of fracture.[10-18] Several studies have shown that ultrasonography has greater accuracy in the midshaft of long bones, including the forearm.[10-12,14-18] We chose to evaluate posterior fat pad elevation and lipohemarthrosis as indirect signs of fracture because it can be difficult to directly visualize fracture at the curved ends of long bones and areas adjacent to joints, and it has been suggested that posterior fat pad elevation may be a reliable indicator of elbow fracture.[17] In addition, variation in the ossification centers of the pediatric elbow makes direct ultrasonographic evaluation of fractures difficult and time consuming for nonradiology sonologists.[15] Our study's purpose was to determine whether point-of-care elbow ultrasonography for posterior fat pad elevation and lipohemarthrosis is a useful diagnostic screening tool for elbow fracture. By applying this screening tool, we may be able to reduce unnecessary

radiographs in patients with elbow injuries. However, radiography will be necessary if the ultrasonography result is positive to confirm the presence of fracture and evaluate the degree of displacement.

According to our data, ultrasonographic evaluation of the posterior fat pad or lipohemarthrosis has higher sensitivity and negative predictive value than specificity and positive predictive value for fracture at the elbow in children and therefore has higher diagnostic utility for ruling out fractures than ruling in fractures. This is in contrast to the findings of Weinberg et al,[17] who examined fractures in children and young adults and found elevation of the posterior fat pad on ultrasonography to have a sensitivity of 80% and specificity of 87% for elbow fracture. However, the Weinberg study examined a small sample of 30 patients with elbow injuries, with a higher fracture rate of 50%. In addition, Weinberg et al[17] did not include evaluation for the presence of lipohemarthrosis.

In comparing the 2 views used to detect the elbow effusion on ultrasonography, it appears that the longitudinal plane is more reliable than the transverse plane for detecting joint effusion.[20] On transverse views, it is possible for one side of the posterior fat pad to be slightly elevated above the lip of the olecranon fossa while the other side is not elevated, with a normal posterior fat pad on longitudinal view. To avoid overdiagnosing an effusion, one should recognize that the entire posterior fat pad needs to be raised above the line connecting both lips of the olecranon fossa on transverse ultrasonographic imaging for the posterior fat pad to be elevated. It has been noted in a study of adolescent and adult patients that there is no association between the size of an elbow effusion and the presence or absence of fracture.[5]

There is evidence in the literature that ultrasonography is more sensitive than radiography in detecting elbow effusion. In a cadaveric study, it was shown that elbow effusions as small as 1 mL could be identified by sonography, whereas 5 to 10 mL of fluid was necessary to visualize an elevated posterior fat pad on radiography.[20] Although ultrasonography can detect smaller effusions in the elbow joint compared with radiography, we would still have the potential to reduce the number of plain radiographs obtained by 48%. However, in our study population, 1 (medial epicondyle) fracture would be missed.

The majority of physicians in our study did not have significant previous ultrasonographic experience, and findings from our study suggest that elbow ultrasonographic skills are attainable with focused training. Ultrasonographic scans were brief, taking an average of 2 minutes to obtain the necessary images. Many of the errors in interpretation of the ultrasonographic images, compared with our expert sonologist interpretation, occurred early in the study. Between the first and last quartile of enrolled patients, the κ for interobserver agreement improved from 0.74 to 0.94, suggesting a steep learning curve. Furthermore, because the incidence and distribution of elbow fractures seen in our study are similar to those of other published studies in children, with the majority being supracondylar fractures,[23,26,27] we believe that our study population is representative of all children with elbow injuries. Given that our study was carried out by a group of novice sonologists with minimal or no previous experience with ultrasonography, we believe that the findings from this study can be applied to other clinical settings.

Findings from our study suggest that point-of-care ultrasonography may be a particularly useful screening tool for elbow fracture in austere environments or other places in which radiography is not readily available. Ultrasonographic machines are becoming more portable, which makes their use ideal in locations that do not have access to radiography. In addition, acute care settings that do not have radiography on site may find point-of-care elbow ultrasonography valuable in determining which patients to refer for additional imaging and which patients can be discharged home without further evaluation. Furthermore, the high sensitivity of elbow ultrasonography found in our study may be useful to reduce the need for radiographs in crowded EDs when the pretest clinical assessment of elbow fracture is low.

Because point-of-care ultrasonography of the elbow depends on the presence of effusion to infer possible fracture, fractures that occur without effusions can be missed if ultrasonography is used as a diagnostic tool. Although the majority of fractures at the elbow will produce joint effusions and elevate the posterior fat pad, medial epicondyle fractures of the elbow may occur without an effusion.[23] In fact, our only missed fracture was a medial epicondyle fracture that was managed nonoperatively. However, 4 of the 5 medial epicondyle fractures in our study did produce an elevated posterior fat pad both on ultrasonography and radiography. Addition of the clinical finding of point tenderness over the medial epicondyle to the positive findings on ultrasonography would improve the sensitivity of this test to 100% for identifying fractures at the elbow and yet still reduce the number of radiographs necessary overall. Although not directly studied, reduction of radiographic studies could be a cost-effective and time-saving measure, and future studies are necessary to further evaluate and validate these findings.

In summary, with focused musculoskeletal ultrasonographic training, novice pediatric emergency medicine sonologists were able to attain the skills necessary to perform point-of-care elbow ultrasonography to evaluate for fracture by assessing the posterior fat pad for elevation and lipohemarthrosis. Point-of-care ultrasonography for elevation of the posterior fat pad and lipohemarthrosis in children was found to be highly sensitive in the setting of trauma, and a negative ultrasonographic result may reduce the need for radiographs in children with elbow injuries. Pediatric emergency physician interpretations of ultrasonographic images had substantial agreement with the interpretation of an experienced pediatric emergency medicine sonologist.

The authors acknowledge and thank the sonologists for patient recruitment and enrollment into the study: Michele Fagan, MD, Daniel Fein, MD, Inna Elikashvili, DO, Rene Forti, MD, Sylvia Garcia, MD, Waseem Hafeez, MD, V. Matt Laurich, MD, Lori Montagna, MD, Charles Murphy, MD, Bret Nelson, MD, Lorraine Ng, MD, Audrey Paul, MD, Ruby Rivera, MD, Catherine Sellinger, MD, Vaishali Shah, MD, Cary Siegel, MD, Louis Spina, MD, Christopher Strother, MD, Young-Jin Sue, MD, Ee Tay, MD, Joy Tun, MD, and Adam Vella, MD.

Supervising editor: Kelly D. Young, MD, MS

Author contributions: JER, LMF, and JWT conceived the study and designed the protocol. HK and JWT supervised the conduct of the study and data collection. All authors undertook recruitment of participating patients and managed the data. JER, HK, JRA, and JWT provided statistical advice on study design and data analysis. JER drafted the article, and all authors contributed substantially to its revision. JER takes responsibility for the paper as a whole.

Funding and support: By *Annals* policy, all authors are required to disclose any and all commercial, financial, and other relationships in any way related to the subject of this article as per ICMJE conflict of interest guidelines (see www.icmje.org). The authors have stated that no such relationships exist.

Publication dates: Received for publication April 20, 2012. Revision received July 3, 2012. Accepted for publication July 20, 2012.

Presented at the Pediatric Academic Societies annual meeting, April 2012, Boston, MA; and the Society for Academic Emergency Medicine annual meeting, May 2012, Chicago, IL.

Address for correspondence: Joni E. Rabiner, MD, E-mail jrabiner@montefiore.org.

REFERENCES

1. Bachman D, Santora S. Musculoskeletal trauma. In: Fleisher GR, Ludwig S, eds. *Textbook of Pediatric Emergency Medicine*. Philadelphia, PA: Lippincott Williams & Wilkins; 2010:1335-1375.
2. Crowther M. Elbow pain in pediatrics. *Curr Rev Musculoskelet Med*. 2009;2:83-87.
3. Griffith JF, Roebuck DJ, Cheng JC, et al. Acute elbow trauma in children: spectrum of injury revealed by MR imaging not apparent on radiographs. *AJR Am J Roentgenol*. 2001;176:53-60.
4. Major NM, Crawford ST. Elbow effusions in trauma in adults and children: is there an occult fracture? *AJR Am J Roentgenol*. 2002; 178:413-418.
5. O'Dwyer H, Sullivan PA, Fitzgerald D, et al. The fat pad sign following elbow trauma in adults: its usefulness and reliability in suspecting occult fracture. *J Comput Assist Tomogr*. 2004;28: 562-565.
6. Pudas T, Hurme T, Mattila K, et al. Magnetic resonance imaging in pediatric elbow fractures. *Acta Radiol*. 2005;46:636-644.
7. Skaggs DL, Mirzayan R. The posterior fat pad sign in association with occult fracture of the elbow in children. *J Bone Joint Surg Am*. 1999;81:1429-1433.
8. Jehle D, Davis E, Evans T, et al. Emergency department sonography by emergency physicians. *Am J Emerg Med*. 1989;7: 605-611.
9. Schlager D, Lazzareschi G, Whitten D, et al. A prospective study of ultrasonography in the ED by emergency physicians. *Am J Emerg Med*. 1994;12:185-189.
10. Dulchavsky SA, Henry SE, Moed BR, et al. Advanced ultrasonic diagnosis of extremity trauma: the FASTER examination. *J Trauma*. 2002;53:28-32.
11. Marshburn TH, Legome E, Sargsyan A, et al. Goal-directed ultrasound in the detection of long-bone fractures. *J Trauma*. 2004;57:329-332.
12. Chaar-Alvarez FM, Warkentine F, Cross K, et al. Bedside ultrasound diagnosis of nonangulated distal forearm fractures in the pediatric emergency department. *Pediatr Emerg Care*. 2011; 27:1027-1032.
13. Chien M, Bulloch B, Garcia-Filion P, et al. Bedside ultrasound in the diagnosis of pediatric clavicle fractures. *Pediatr Emerg Care*. 2011;27:1038-1041.
14. Hubner U, Schlicht W, Outzen S, et al. Ultrasound in the diagnosis of fractures in children. *J Bone Joint Surg Br*. 2000;82: 1170-1173.
15. Moritz JD, Berthold LD, Soenksen SF, et al. Ultrasound in diagnosis of fractures in children: unnecessary harassment of useful addition to x-ray? *Ultraschall Med*. 2008;29:267-274.
16. Patel DD, Blumberg SM, Crain EF. The utility of bedside ultrasonography in identifying fractures and guiding fracture reduction in children. *Pediatr Emerg Care*. 2009;25:221-225.
17. Weinberg ER, Tunik MG, Tsung JW. Accuracy of clinician-performed point-of-care ultrasound for the diagnosis of fractures in children and young adults. *Injury*. 2010;41:862-868.
18. Williamson D, Watura R, Cobby M. Ultrasound imaging of forearm fractures in children: a viable alternative? *J Accid Emerg Med*. 2000;17:22-24.
19. American College of Emergency Physicians. Policy statement: emergency ultrasound guidelines. *Ann Emerg Med*. 2009;53:550-570.
20. De Maeseneer M, Jacobson JA, Jaovisidha S, et al. Elbow effusions: distribution of joint fluid with flexion and extension and imaging implications. *Invest Radiol*. 1998;33:117-125.
21. Miles KA, Lamont AC. Ultrasonic demonstration of the elbow fat pads. *Clin Radiol*. 1989;40:602-604.
22. Tsung JW, Blaivas M. Rapid screening for the posterior fat pad sign in suspected pediatric elbow fractures using point-of-care ultrasound: a "FAST exam" for the traumatized elbow. *Crit Ultrasound J*. 2010;1:111-116.
23. John SD, Wherry K, Swischuk LE, et al. Improving detection of pediatric elbow fractures by understanding their mechanics. *Radiographics*. 1996;16:1443-1460.
24. Zuazo I, Bonnefoy O, Tauzin C, et al. Acute elbow trauma in children: role of ultrasonography. *Pediatr Radiol*. 2008;38:982-988.
25. Arkin CF, Wachtel MS. How many patients are necessary to assess test performance? *JAMA*. 1990;263:275-278.
26. Houshian S, Mehdi B, Larsen MS. The epidemiology of elbow fracture in children: analysis of 355 fractures, with special reference to supracondylar humerus fractures. *J Orthop Sci*. 2001;6:312-315.
27. Landin LA, Danielsson LG. Elbow fractures in children: an epidemiological analysis of 589 cases. *Acta Orthop Scand*. 1986; 57:309-312.