in sports for at least three weeks and only after medical advice. It is also important to inform your doctor of your initial head injury.

LEVEL 1	No physical activity /complete rest
LEVEL 2	Low levels of physical activity i.e. *symptoms do not come back during or after the activity*. e.g. walking, light jogging, light stationary biking, light weightlifting (lower weight, higher reps, no bench, no squat).
LEVEL 3	Sport specific training or Moderate levels of physical activity with body/head movement e.g. running in football, moderate jogging, brief running, moderate-intensity stationary biking, moderate-intensity weightlifting (reduced time and/or reduced weight from your typical routine).
LEVEL 4	Heavy non-contact physical activity / training drills e.g. sprinting/running, high-intensity stationary biking, regular weightlifting, routine non-contact sport-specific drills
LEVEL 5	Full contact in controlled training/practice.
LEVEL 6	Full contact in games/ Return to competition.

Adapted from McCrory P, et al. Br J Sports Med 2013;47:250–258.

doi:10.1136/bjsports-2013-092313

FRACTURES (SEE ANKLE AND FOOT, SHOULDER AND CLAVICLE, KNEE, NECK, WRIST, SEDATION, FALLS AND HAND INJURIES

This handbook cannot give an exhaustive account of fracture management, however guidelines about the management of common fractures can be found later in this section. As well as this, McRae provides easy-to-follow guidelines in the department's copy of "Practical Management of Fractures". Consult these first but ask for advice if in doubt.

Here is some general information about fracture management:-

Our Specialist Fracture Service is provided by RVH Fracture Clinic RBHSC Children's Fracture Clinic

Adult Fractures

- Patients who may require urgent operative treatment should be referred to the fracture clinic immediately; this includes all compound fractures (except finger tip injuries. These can be managed in the Emergency Department)
- Fractures that are badly displaced/angulated, intra-articular or comminuted should be discussed with RVH (excluding elderly patients with Colles fractures)
- All ankle fractures that are bi-malleolar, medial malleolar or associated with talar shift should be discussed with RVH
- Acute tense haemarthrosis should be discussed with the fracture clinic. Fractures around the tibial plateau (condyles) are easily missed – be vigilant; all should be referred
- All fractured neck of femurs should be referred to RVH for admission.
- All consults with the RVH should be recorded on the Emergency Department notes and fracture doctor's name recorded
- NSAIDs may inhibit fracture healing and should NOT be prescribed.
- All patients over 18 with lower limb fractures should undergo VTE assessment. There is a specific form for this assessment in Antrim and should be followed until the regional assessment form becomes available later this year.
- For all patients diagnosed with a fracture not requiring urgent intervention, tell patients that we have requested # clinic follow up but that the date will be dependent on the triage system in Whiteabbey Hospital.

Looking after Children's Fractures

- Children's fractures are hard to see - when in doubt plaster!
- When children fall onto their outstretched hand while roller-blading, biking etc, they usually sustain a greenstick fracture distal radius at least. Use a Futuro Splint if you can't see a fracture. Check elbow!
- Refer torus (buckle fracture no displacement) fractures to the Fracture clinic.
- Children under three can remove short arm pops - use long arm pop with this age group. If slightly older children return with short arm plaster problems then place in a long arm pop.
- If you discharge a child with a diagnosis of soft tissue injury, tell parents to return the next day if their child still has significant pain - soft tissue injuries in children clear up very quickly.

- Significant displacement or angulation and all compound fractures should be discussed with RBHSC

Liaison with Plastic Surgery (UHD)

Hand fractures that may require internal fixation are usually referred to Plastic Surgery. These include all unstable/rotated finger fractures. Assume this if oblique or spiral on x-ray, displaced on x-ray, malrotation or deformity clinically or complete inability to flex. Fractures involving more than one third of IPJ surface should be referred. Fractures of distal phalanx are managed at the Review Clinic.

Older patients

- Elderly patients with fractures often require a care package via the social worker because of a short term increase in dependency (e.g. reduced mobility due to # vertebrae, pubic rami or loss of independence due to an upper limb fracture). Hospital admission shouldn't be required for nursing needs alone.
- Always look out for unexplained or recurrent falls – more about this under "Falls" in clinical section.

Query fractures, small avulsion fractures

- If you aren't sure about these, treat with sling, backslab, non weight – bearing etc. Explain that there may be a "minor injury to the bone" but that the diagnosis will not be certain until a second x-ray is taken after ten days. Refer to the Emergency Department Review Clinic for this.
- Don't put a leg in plaster if the patient is over 45 or has other risk factors for DVT unless there is a definite fracture. Use strapping and crutches.
- The management of clinical scaphoid fractures is important (see wrist injuries).
- Look out for the 'fat pad sign' in the elbow as a pointer to radial head # (this is the most commonly missed fracture). Treat with collar + cuff and x-ray at ARC day 7-10. A clinically fractured elbow will not have a normal range of movement. Treat if in doubt.

Reductions in the Emergency Department

- Only uncomplicated wrist fractures (such as Colles Fractures) should be reduced in the Emergency Department
- Analgesia / sedation options include:
    - Entonox
    - Haematoma block
    - Conscious sedation (assess suitability using sedation proforma, also use this to facilitate safe sedation practice – MUST have senior ED doctor signed off to perform sedation and separate procedure doctor)

- A post –reduction plaster should be A SPLIT FULL CAST (never unsplit POP).
- POP advice must be given - all patients re-attending with symptoms suggesting a tight plaster should have their cast opened immediately after triage.
- Need fracture clinic appointment within 1 week
- Failed reductions should be discussed with RVH
- Fracture reductions may be deferred until next day if no neurovascular compromise is found. Admit these patients to the Obs ward overnight for analgesia and fast from 6am.
- Reduction of dislocations must be performed in a timely fashion.

SOFT TISSUE INJURIES (SEE ALSO FRACTURES, NECK, ANKLE AND FOOT, SHOULDER AND CLAVICLE, KNEE, LOW BACK PAIN)

It is often minor injuries that present doctors new to the Emergency Department with the most difficulty.
Soft tissue injuries are satisfying to treat – they often happen to active, healthy people, especially sportsmen and women who are highly motivated to recover.

- (dolor, rubor, tumour, calor) so the injury will look and feel progressively worse over the next 2-5 days. This process responds to rest – ice (15 mins with frozen peas qid!)-compression bandage – elevation and non-steroidal drugs help also.
- Regain NORMAL MOVEMENT. After the inflammatory phase, gradual return to normal movement is encouraged. Patients must return to normal activities as soon as possible or stiffness and wasting will deteriorate. Often this is just a matter of common sense but for more complicated injuries, physiotherapy may help. This phase may take several weeks.
- Return to SPORT. Sports people or manual labourers will need further rehabilitation to regain the muscle strength and proprioception that they will have lost during phases one and two of recovery. Failure to follow a rehabilitation programme at this stage will cause injury.
- Physios (either hospital or club) can supervise this. There is also information on the internet about self help for various sports and injuries.

Here are a few commonly encountered soft tissue injuries - all of them are suitable for referral to physiotherapy, especially if severe:

A "**contusion**" is a bruising injury to soft tissue generally caused by a direct blow (e.g. multiple contusions after an RTA). More extensive bleeding leads to a haematoma that may be localised, leading to a fluctuant swelling or diffuse, leading to an area of woody-hard muscular induration.

A "**sprain**" is a ligament injury, e.g. ankle sprain, acute neck sprain. The commonest sprains involve the lateral ligaments of the ankle and the medial collateral ligament of the knee.

Ligament Injuries are often classified according to severity
Grade One: Pain on stressing but no laxity (no significant tear)
Grade Two: Laxity with an end-point (partial tear)
Grade Three: Laxity with no end point (complete tear)

A "**strain**" is a muscle tear, either intrinsic e.g. an acute lumbar strain may be "intrinsic" (sudden stooping) or "extrinsic" (falling from a height). This can result in diffuse or discrete bleeding, loss of power or function, a palpable gap and spasm/pain.

Explain the natural history of soft tissue injury (above) and advise that symptoms may last for months although they should not get worse. Patients should return immediately if worse or after ten days if not improving at all – this suggests a missed fracture etc. The appropriate advice sheet should be given (a selection of these are available).

NECK (SEE ALSO SOFT TISSUE INJURIES, FRACTURES)

Pain without injury:

- Usually muscular (Wry Neck)
  NSAID, massage, heat, very urgent physiotherapy
  Consider ENT cause in kids
- Occasionally caused by Cervical disc prolapse
  Severe pain with nerve root pain +/- signs
  If neurology, discuss with on-call orthopaedics

Suspected Neck Injury

- Patients who may have thoracic or lumbar injury should lie flat on a trolley *(never a long board - this is for transport & lifting only)*
- Cx spine x-ray unless no mechanism for spinal injury, full range of movement and no tenderness
- Acute Neck Sprain – tends to get worse over a few days - NSAID, mobilise, reassure

- Spinal Fractures-Patients who may have cervical spine injury should lie flat on a trolley with neck
  immobilised in cervical collar, sandbags and tape until x-ray and examination exclude this. The first (lateral) x-ray will require traction on the arms so that C7/T1 can be seen.
  Do not accept non-diagnostic x-rays – seek senior advice.
- When x-rays discuss spinal injury, seek advice

Cervical spine x-rays

Cervical spine x-rays do not need to be ordered if all the following are met (NEXUS criteria):

No posterior midline tenderness
No evidence of intoxication
Normal level of consciousness
No focal neurological deficit
No painful distracting injuries

If continuing concerns re. unstable neck injuries **Continue** spinal

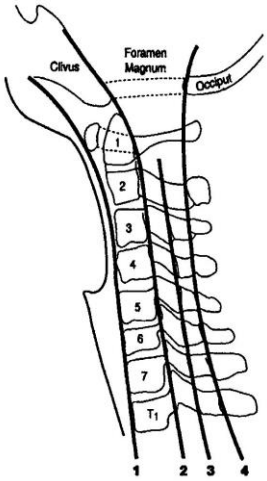

Cervical spine review alignment
The cord lies between 2 and 4

1. Anterior vertebral line.
2. Posterior vertebral line (anterior wall of the spinal canal).
3. Facet line.
4. Spino-laminar line (posterior wall of the spinal canal).

immobilisation & x-rays. Link with senior ED clinician. For further reading http://www.fphc.co.uk/

Penetrating Neck Wounds

- All penetrating wounds require exploration in theatre
- Never probe, cover –Air embolism!!
- Think of impending airway obstruction. Anaesthetic assessment.

FACIAL INJURIES

The airway is a risk with major facial injuries – request anaesthetic assessment!

Malar Fractures
- Blow to the cheek
- Tender, limited upgaze, numbness.
- Facial X-rays will confirm diagnosis (sinus is cloudy compared to other side)

Maxillary fractures
- Usually high energy impact
- Facial swelling
- Malocclusion
- Epistaxis
- Facial X-rays should be taken but may not help
- Facial bone instability may be found on examination

Mandibular Fractures
- Assault or RTA
- Malocclusion
- Pain on clenching teeth
- OPG shows fracture (often bilateral) if you look carefully

Blow-out fracture
- Blow to eyeball
- Limited upgaze +/- diplopia
- Soft tissue (teardrop) visible on Facial x-ray

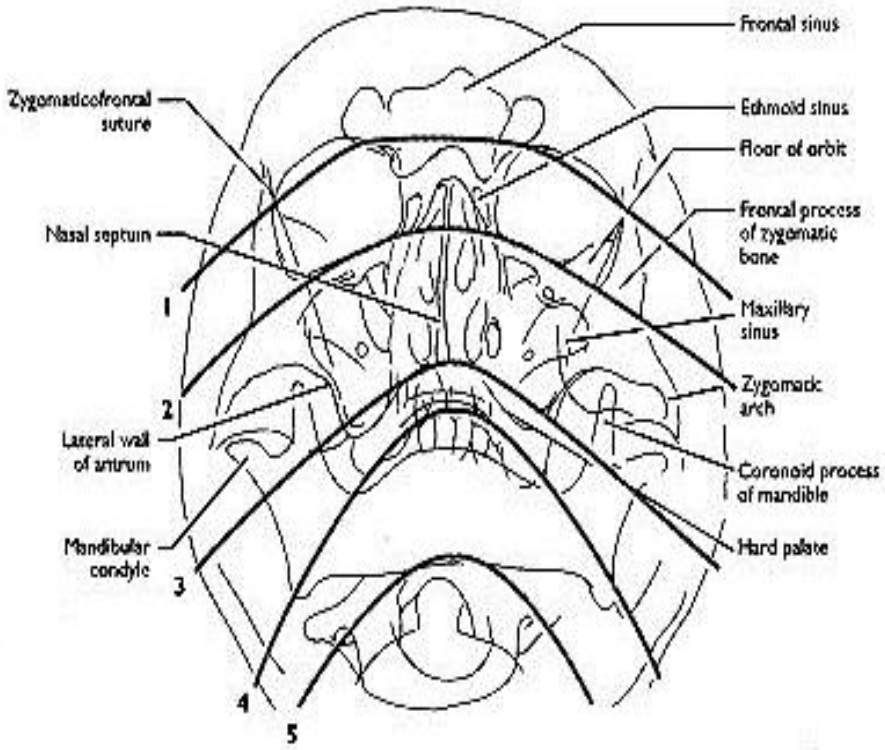

ABCs of the Facial X-ray

A: Adequacy
Alignment - Check lines 1-5 (see above)

B: Bones

C: Cartilage and joints
Zygomaticofrontal suture

S: Sinuses - Opacification and air-fluid levels
Soft tissue - Swelling and Foreign bodies

Le Fort's Fractures of the Face

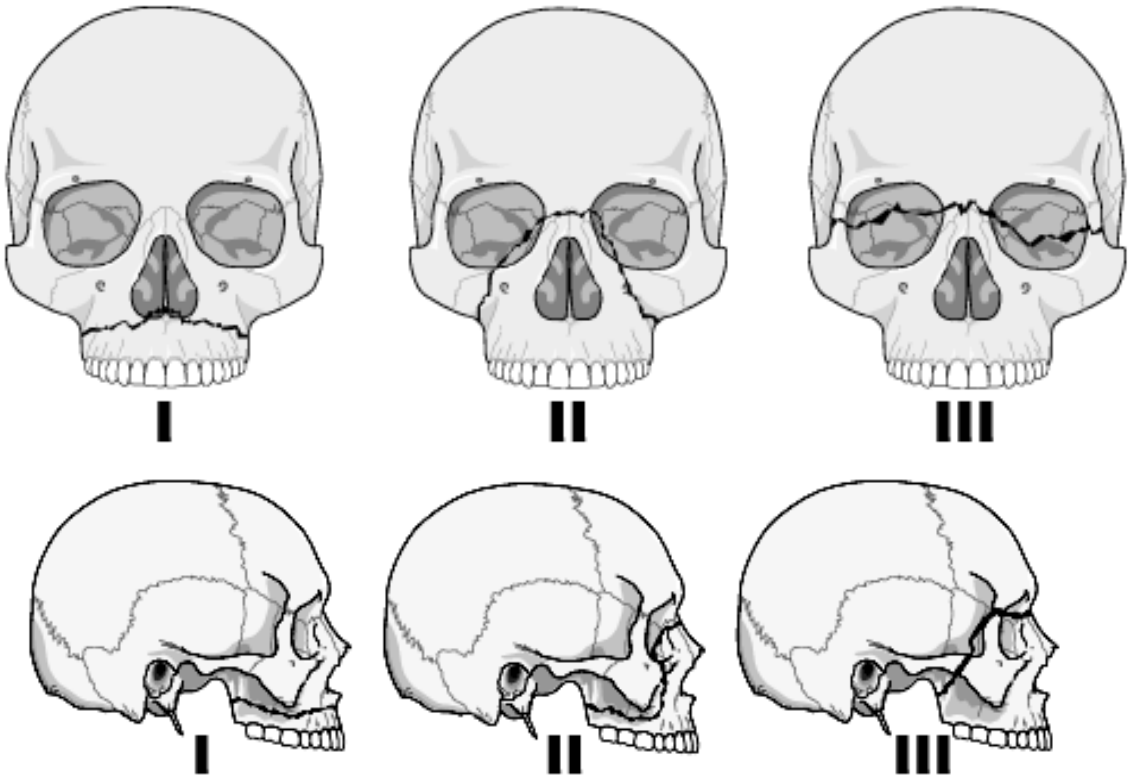

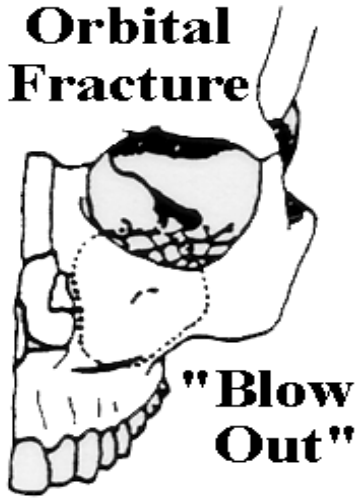

Indirect signs of maxillary fracture

*** Soft tissue swelling**

*** Opacification of the maxillary sinus is usual in fractures which affect its wall and an air-fluid level is usually seen**

*** Soft tissue emphysema is a rare but useful sign. It provides positive evidence of a fracture of the nasal cavity or one of the paranasal sinuses. It may show as multiple small radiolucent areas in the soft tissues. Alternatively air may enter the orbit to outline the eyeball**

All definite or suspected facial bone injuries should be discussed with the maxfax SHO in the Ulster hospital urgently (NOT the patient's own dentist)

DENTAL EMERGENCIES (SEE ALSO FACIAL INJURY)

There is a very limited emergency dental service for patients. The details of this are kept in the Triage cubicle. Dentists are supposed to provide emergency cover for their patients but some of their answer-phones advise patients to attend Antrim Emergency Department! You must be able to provide basic emergency care. Advise patients with a non-traumatic dental problem to contact their own dentist to arrange follow-up.

Dental pain
Give strong analgesia. Clove oil may be of benefit. Patients are advised to attend their dentist.

Out of hours relief of dental pain clinic **phone 25663500.** There is also a clinic in BCH.

Dental Infection
Give strong analgesia and antibiotics (check BNF)
NB LUDWIG'S ANGINA, AN INFECTION CAUSING SWELLING OF THE FLOOR OF THE MOUTH AND POTENTIAL SUDDEN-ONSET UPPER AIRWAY OBSTRUCTION – ADMIT – CONTACT ENT!

Dental Haemorrhage
Patient should bite on a roll of gauze
Consider coagulopathy
Follow BNF guidelines for bleeding in warfarinised patients where relevant
Seek advice from Maxfax SHO in the Ulster Hospital

Trauma
Dental trauma can be referred to RBHSC (under thirteens) or UHD (any).
Avulsed second teeth should be replaced in Triage prior to seeking dental advice. If this is impossible, keep tooth in N Saline.

SHOULDER AND CLAVICLE

Non-Traumatic Shoulder pain
Septic arthritis must be excluded in all atraumatic joint pain – temp + ESR.
"Frozen shoulder" is caused by a variety of pathologies all characterised by pain (especially at night) and restriction of movement at the shoulder joint. The two commonest causes are (a) Capsulitis, involving the rotator cuff muscles, characterised by equal restriction of abduction, internal & external rotation and (b) Supraspinatus tendonitis with pain on restricted abduction only.

Use collar & cuff + NSAD and physio referral. Evidence for injection now inconclusive. Shoulder pain may be referred from the neck – examine as well.

Injury around the Shoulder

Dislocated Shoulder

Commonly anterior but can be posterior (x-ray looks fairly normal but light-bulb shaped humerus and clinical suspicion). Can occur as the result of seizure/collapse. Always ask for a glenoid view. Normal glenoid view is below.

Shoulder may be reduced under self-administered N_2O from entonox bottle OR iv sedation (not both!). Consent must be obtained. Sedation must be performed in resus by senior doctor with airway and sedation competencies. Aftercare – inside-clothes collar & cuff or polysling and FC review.

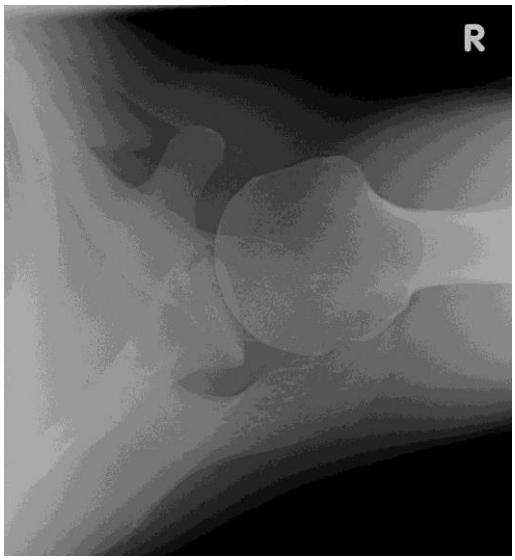

Consider Cunningham's technique which is rapidly being adopted by many ED consultants:
http://lifeinthefastlane.com/cunninghams-shoulder-relocation/

Clavicle Fracture

Inside-clothes sling or C+C, analgesia and fracture clinic 7-10 days.
Tell patient that they will have a permanent bump on their shoulder but that these are rarely troublesome.
Don't panic about marked deformity unless a spike of bone is tenting skin or there is a neurovascular problem (discuss the latter with RVHFC)

WRIST INJURIES (SEE ALSO FRACTURES, SEDATION, SOFT TISSUE INJURIES, FALLS)

Colles' Fracture

Did you remember that Abraham Colles described dorsal angulation, impaction and rotation of the distal radius + ulnar styloid avulsion? Strictly speaking all distal radial fractures are not Colles' Fractures!

Emergency Department treatment is only suitable for low-impact fractures without communition or joint involvement –other distal radial fractures should be discussed with RVH FC. >15^0 angulation and/or impaction of the distal radius usually requires reduction. You will be taught how to assess, reduce and discharge patients with this injury – do not undertake this procedure unsupervised unless a consultant has told you that you are competent to do this procedure unsupervised.

Haematoma Block

This procedure can be used to manipulate closed Colles'-type fractures in over 45yo

This procedure should not be performed by a solitary doctor; a qualified nurse or plaster technician must be present and a second doctor rapidly available.

Method

1. The fracture must be a less than 24 hours old, no signs of infection.

2. Patient should be monitored (in case of inadvertent IV injection of lignocaine).

3. Prepare the patient, explain the procedure, and obtain consent. <1% (1 in 1000) chance of osteomyelitis

4. The forearm should be prepped with iodine. The operator must wear surgeon's sterile gloves.

5. Prepare 10ml 2% lignocaine in a 10ml syringe and green (21G) needle.

6. The anaesthetic should be injected directly into the fracture haematoma: Locate the fracture site by palpation. You should feel the needle coming into contact with the jagged bone ends as it passes between them to a depth of 3-4cm. Aspirate some of the haematoma from the fracture site (but be aware that it is not possible to be certain that you are not in a vein rather than the haematoma!).. IF done under bright light, the fat globules will be visible streaming up centre of syringe barrel. Barbotage increases efficacy.
a.Inject-½volume
b.Aspirate-fully
c.Repeat-(upto7times).
This ensures good mixing across all sides of # & does not make the bone edges less distinct during manipulation. \

Cont ...

7. **Inject VERY SLOWLY to minimise the risk of complication**. The wrist will become tight. Put a sterile dressing (e.g. mepore) over puncture site(s)

8. Wait for block to take effect - on average 5-10 minutes. Check analgesia before proceeding to manipulate. Supplement with "Entonox" if necessary but if patient complains of persistent pain, get senior help; do not proceed with manipulation.

9. The patient can be mobilised after their check x-ray if they feel ready to get up.

Smith's Fracture

"Upside-down Colles". If you don't view all your lateral wrist x-rays thumb-down you will miss this! Discuss with RVHFC –should be immobilised in split LAPOP post reduction but this should only be undertaken by experienced doctors.

Scaphoid Injury

Clinical: All painful wrists following trauma with any scaphoid signs must have wrist and 'scaphoid views'. You must always examine for scaphoid injury in all the following ways:

- ASB tenderness or swelling
- Pain on telescoping and impinging thumb vs 1st MC
- Pain on flexion + ulnar deviation
- Pain over palmar scaphoid

Management: 1. Clinical Scaphoid (i.e. signs but no x-ray changes).
If there is strong suspicion (more than 1 sign) –SAPOP and bring back to nurse practitioner day 14.
If there is mild-moderate suspicion (1 sign) – Thumb-o-prene splint and bring back to nurse practitioner day 14.
2. Radiological scaphoid fracture.
If you see a fracture SAPOP and FC – they are usually six-eight weeks in plaster.

Other Fractures

- Undisplaced wrist fractures and greensticks = POP, sling and FC
- Other wrist fractures should be discussed with RVHFC.

HAND INJURIES AND INFECTIONS (SEE ALSO FRACTURES)

All hands should be examined for tendon function, sensation (pin-prick) and joint swelling. Record **occupation and dominant hand**. Uniquely, hand

injuries should be x-rayed even if fracture unlikely - if only one finger involved ask for finger XR rather than hand. Most significant hand injuries benefit from elevation in a volar slab and high sling for a few days (i.e. until the next Review Clinic).

Flexor tendon injuries, significant amputation or degloving, nerve damage, high-pressure injection injuries and suppurative tenosynovitis or multiple hand fractures should be referred to the Plastics Registrar (Ring UHD).

Mallet Finger

Where the ability to extend the distal phalanx is lost. X-ray and if there is a fracture involving more than one third of the joint surface refer to Plastics. Otherwise treat with a well-fitting "mallet splint" and next ARC appointment. The patient must not remove the splint. Six weeks' treatment is usually required

Finger Sprains and volar plate injuries

These generally affect PIP joints - any swelling here, treat as sprain. If hyper-extension ("staving") injury treat as VPI.
Improper immobilisation leads to a chronic spindle-finger and a disgruntled patient. All with swelling should have x-ray then neighbour strapping and next ARC. NSAIDs may help.

Extensor tendon injuries

These may be referred to the General Surgeons or Plastic surgeons for repair.

Flexor tendon injuries

Don't forget to test both FDS and FDP - check flexion at DIPJ for profundus and flexion with uninjured fingers hyperextended for superficialis. Refer to Plastic Surgery in UDH

Hand Infections

- acute paronychia - incise around the cuticle and nail-fold in the shape of the nail until pus expressed.
- Pulp (finger tip) abscesses should be drained by twirling a sharp-pointed scalpel round on them.
- suppurative tenosynovitis is a very serious condition which usually follows a trivial or forgotten finger prick. The finger is swollen, stiff and very painful - especially when bent back. –REFER TO PLASTICS
- Deep palmar infection – systemic upset, redness and swelling, pain when fingers are straightened – REFER TO PLASTICS

Finger tip injuries (FTI)

These tend to look worse than they are. Providing no bone is exposed they can be dressed, immobilised and reviewed at next Emergency Department Clinic.

Leave children's nails in situ. Adults' nails should generally be removed if injured but this can be done next day if you are not sure what to do. Antibiotics are often indicated. If bone is exposed and you are unfamiliar with management, contact surgical SHO. Finger terminalisation is not an ED procedure.

- **Amputation**. Providing no bone is exposed the finger can be dressed with "mepitel", immobilised and reviewed at the next Emergency Department clinic. If bone is visible refer to plastics. Refer to plastics also if amputated part is available to assess possibility of re-implantation (usually not feasible).
- **Partial amputation (Adults)**. This presents as a crush, a laceration or an avulsion of the nail. Primary repair of nail bed required if significant laceration. Refer to plastics if bone visible. Follow-up in ED if no bone visible – dress with mepitel and immobilise
- **Partial amputation (Child**). Primary repair is rarely necessary – you should consult a senior doctor or the plastics SHO if there is a deep nail bed laceration. Other cases treated conservatively (as described above).
- Antibiotics (Co-amoxiclav) are indicated if there is a compound fracture or if you suspect that the bone is exposed.

Patients/parents will be particularly anxious about fingertip injuries. You must explain the prognosis and management plan very carefully to them. Advice is usually along the lines given below:

- FTIs are generally not as bad as they look and, although slow to heal, the final result is usually much better than they expect.
- In the case of complete amputation, the finger will be treated conservatively at first but, if it does not respond, amputation of a small section of their finger may be required subsequently.
- In the case of Partial amputation (Adults), you can discuss the options of nail removal and meticulous nail bed repair versus conservative treatment which will almost certainly result in permanent deformity of the nail. Many patients prefer to risk the latter!
- If you are dealing with partial amputation in a child you must explain that conservative management is usually as successful as primary repair but

that dressings must be looked after carefully and that very occasionally the fingertip will eventually be lost because of the nature of the injury.

FTIs generate a lot of complaints so if a patient/parent expresses concern about your management plan you should discuss the case with an Emergency Department consultant or plastic surgeon.

KNEES (SEE ALSO LIMPING CHILD, FRACTURES, SOFT TISSUE INJURIES)

1. Trauma

Red Flags – refer to RVHFC
- Fractured Tibial Plateau
- Displaced fracture patella
- Acute Haemarthrosis
- Penetrating injury
- True locking
- Dislocated Knee (not patella!)

Key Points in History
- Mechanism is important: Direct blow (muscles and bones), stretch (ligaments) and/or twist (cartilage)?
- True locking or giving way are the key symptoms of loose body or cartilage tear
- Rapid swelling = haemarthrosis; gradual swelling = effusion
- Dislocations may relocate spontaneously so history may be the only remaining clue – patient may recognise description of patella or knee joint dislocation

Rapid Examination
- Look and feel for swelling, inflammation or wounds
- Palpate along the joint line for specific areas of tenderness(menisci)
- Test movement, especially extension – can the patient lift their knee off the bed (ie test extensor mechanism) ?
- Stress the ligaments (mainly ACL and MCL) for any sign of a tear (see Soft Tissue Injury)

Management
- Significant haemarthrosis should be discussed with RVHFC
- Suspected rupture of extensor mechanism; x-ray patella and discuss with RVHFC

- Dislocated patella can be reduced immediately with entonox and immobilised in POP cylinder. Refer to Fracture Clinic
- Dislocated knee must be reduced immediately – entonox and morphine if not able to quickly and safely sedate. Even if reduced pre-hospital, urgent vascular assessment is indicated - discuss with RVHFC
- Suspected cartilage or ligament tear without haemarthrosis; Torn ligament cannot be excluded in the acutely painful knee because ligaments cannot be adequately stressed. Explain this to the patient. NWB crutches and urgent physio. Ask GP to consider urgent orthopaedic referral if patient does not respond.
- All suspected penetrating trauma should be referred to RVHFC
- Fractures around the knee are rare but commonest after RTA. They can involve tibial plateau, patella, neck of fibula – discuss with RVHFC

Ottawa Knee Rules

A knee X-ray series is only required for knee injury patients with *any* of these findings:

1. Age 55 or older
2. Isolated tenderness of the patella (that is, no bone tenderness of the knee other than the patella).
3. Tenderness at the head of the fibula.
4. Inability to flex to 90 degrees.
5. Inability to bear weight both immediately and in the emergency department (4 steps; unable to transfer weight twice onto each lower limb regardless of limping).

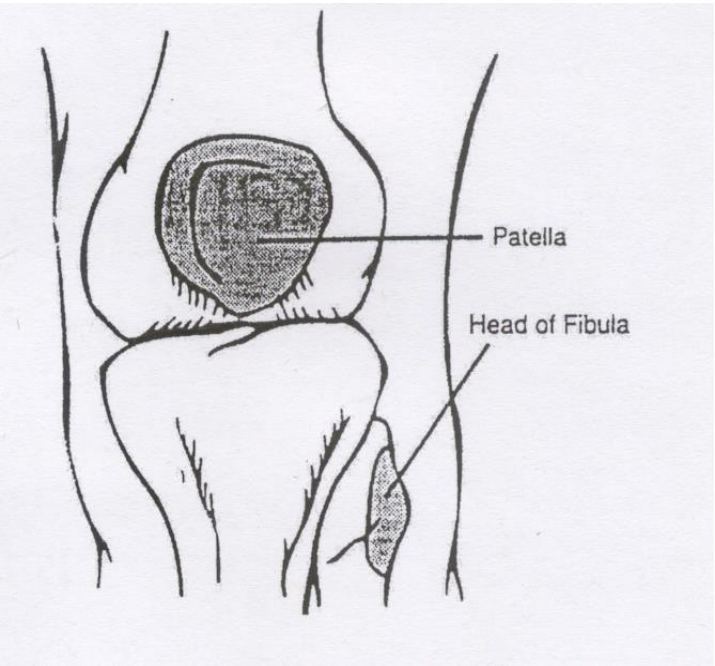

2. Non-traumatic knee pain

KNEE X-RAYS ARE NOT INDICATED FOR ATRAUMATIC KNEE JOINT PAIN BUT REMEMBER THAT HIP PAIN MAY BE REFERRED TO THE KNEE.

Pre-patellar Bursitis

Learn to distinguish *bursitis,* which is obviously red and well demarcated, from a *joint effusion* which is more diffuse and associated with greater reduction in movement. *Bursitis* can be inflammatory or infective(less common) and can be treated expectantly with anti-inflammatories +/- antibiotics unless severe. Severe or non-responding bursitis may require I&D – discuss with senior ED doctor.

Knee joint effusions

The following knee effusions require immediate aspiration to exclude septic arthritis:

- All recently injected/aspirated joints
- All warm, tender joints with effusion
- All effusions if WCC or ESR raised
- Suspicion of TB
- All effusions in immuno-compromised patients (ADMIT)

A hot joint may be due to septic arthritis, Reiter's disease, unexpected haemarthrosis or crystal arthropathy but you have to assume sepsis if the aspirate is cloudy-looking until negative cultures obtained. If the joint aspirate is straw-coloured, treat with NSAIDs and rest. Patient must be reviewed by GP. Blood usually follows forgotten minor trauma in a patient with degenerative disease and can be treated in the same way. Turbid joint fluid requires admission/discussion with a Rheumatologist.

Anterior knee pain

Causes include chondromalacia patellae(quads wasting), recurrent lateral dislocation of patella (apprehension test), patellar tendonitis (localized to tendon), Osgood Schlatter's ("sporty kids" + swelling and tenderness over tibial tubercle), Osteochondritis Dissecans (locking joint – do an x-ray!).
Rest, NSAID, Physio opinion, back to GP!

Locked Knee

- Inability to extend knee beyond a certain point.
- Pseudo-locking (esp. children and young adults) responds to iv Pethidine followed by slow and <u>gentle</u> sustained pushing downwards into full extension.
- True Locking (usually older patient or known loose body / meniscus tear) does not usually respond to iv pethidine. *Must be discussed with RVHFC urgently.*

ANKLE AND FOOT (SEE ALSO FRACTURES, SOFT TISSUE INJURIES)

1. Ankle Injuries

History:
- Snap, crack or pop? – suggests significant bone or ligament injury

Examination:
- Deformed or dislocated? Give entonox/IV morphine and pull straight at once or get help at once, then apply backslab POP – x-ray comes afterwards!

- Compound fracture? –Inadine, gauze and tape, iv Co-Amoxiclav, describe wound to fracture unit (Wound >Icm? contused, dirty or neurovascular complications?)
- Other cases- Ottawa ankle rules to decide if x-ray is needed (usually not needed). Next page.

First Aid
- Ice in a glove for ten minutes + analgesia

Management of sprains and fractures
- All fractures (except *) - SL backslab POP and discuss with RVH urgently
- If extremely swollen, can't weight bear at all or small avulsion-type fracture*(<0.5cm) use dynacast splint and review at ARC/CRC
- Vast majority – RICE advice (see soft tissue injuries) and DTG. Mobilise and self care for up to six weeks unless problems. Decision flow chart:

Is imaging appropriate?

If NO bony injury:

Grades of ankle sprain			
Sign/symptom	*Grade I*	*Grade II*	*Grade III*
Ligament tear	None	Partial	Complete
Loss of functional ability	Minimal	Some	Great
Pain	Minimal	Moderate	Severe
Swelling	Minimal	Moderate	Severe
Ecchymosis	Usually not	Common	Yes
Difficulty bearing weight	None	Usual	Almost always

GRADE I
- Analgesia
- PRICE advice
- Double Tubigrip
- NSAIDS x 72 h if no contra-indications
- Patient advice leaflet

GRADE II
- As per Grade I PLUS:
- Crutches?
- Need for physio?
- Recurrent? Need for orthopaedic review?

GRADE III
- Analgesia
- PRICE advice
- NSAIDS x 72 h if no contra-indications
- Patient advice leaflet
- Crutches
- Supervised physiotherapy
- Need for cast/ Aircast brace?
- R/W 10 days

---

2. Foot Injuries

Fractures

- Avulsion fracture 5th MT base and isolated metatarsal fractures – Strapping and crutches if minor or POP if major. Refer to FC. Transverse (non-avulsion) fractures of 5th MT are an exception – discuss with RVHFC.
- Other foot fractures or abnormal separation of metatarsals – discuss with RVH FC
- Calcaneal fractures are serious and very easily missed- always look at the calcaneus on the x-ray and examine it clinically. There may be no fracture line, just a flattened appearance. Os calcis x-rays are indicated if suspicion.

Non –traumatic foot pain

This is a high risk symptom

- *Septic arthritis must always be excluded – temp and ESR*
- Careful vascular assessment of whole leg (+capillary refill time)

- Focal bone tenderness + raised ESR – consider osteomyelitis
- Non-specific cases – Footwear advice, NSAID, crutches, GP review

Foot pain without evidence of serious underlying cause usually responds to a change of footwear

Ottawa Ankle and Foot Rules

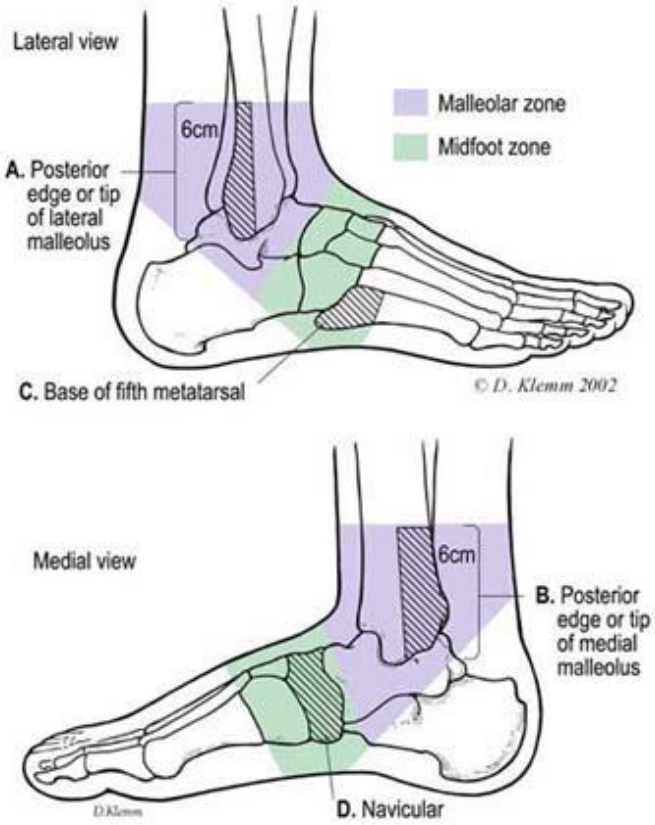

Ankle X-ray required if:

1. Pain in malleolar zone and
2. Bony tenderness at A or B
3. or an inability to weight bear immediately

Foot X-ray required if:

1. Pain in mid-foot zone and
2. Bony tenderness at C or D
3. or an inability to weight bear immediately

WOUNDS (SEE HAND INJURIES, IMMUNISATION, SUSPECTED EXPOSURE TO BBV)

General Facts about Wound Care

- Tetanus +/- hepatitis, anti-bacterial prophylaxis should be considered
- Profuse bleeding can be controlled by a direct pressure dressing – consider underlying arterial damage even if pressure has arrested haemorrhage. Seek senior advice if necessary. Bleeding scalp wounds usually respond to skin suture and a temporary pressure dressing.
- Wounds must be thoroughly cleaned and explored (tourniquet if necessary)
- Where primary closure is planned, lacerations that are not right through dermis and less than 1cm long may be suitable for steri-strips or tissue adhesive glue. Larger or deeper wounds require suture or staples. Steri-strips or tissue adhesives should not be used across joints or Langers lines
- Lacerations crossing the vermilion border of the lip must be sutured meticulously –seek senior advice

Wound Breakdown

- Infection, ischaemia and foreign body prevent wound healing – if these are likely, suturing may not be the best option or delayed primary suture may be considered. Seek senior advice.
- All wounds caused by glass (including by mirrors) must be x-rayed (FB)
- Pre-tibial wounds should not be sutured (ischaemia)
- Seek senior advice before suturing flap lacerations (ischaemia)
- Grossly contaminated wounds and most bites should not be sutured –seek advice (infection)

Some common wounds / injuries and treatments are shown below.

Condition	Site	Treatment	Healing Time
Laceration	Face	Glue - superficial, <3 cm, straight, tension free)	
		Steristrips - straight, tension free	5 days
		Sutures - 6'0, non-absorbable	3-5days
	Scalp	Glue - superficial, <3 cm, straight, tension free	
		Sutures - 3'0 non-absorbable	7 days
		Staples	7 days
	Over joints	Sutures - 3'0 and 4'0	10-14 days
	Hands	Sutures – 4’0 and 5’0	10 days

	Trunk Limbs	Sutures – 3'0 or staples Sutures – 3'0 or staples	10 days 10 days
Sprains	Ankle	DTG for 2-3 days Dynacast / elastoplast strapping for 2-3 days	6-8 weeks 2-3 mths
	Knee	Grade 1 tear - DTG / Arthropad (2-3 days) Grade 2 tear - DTG / Arthropad (consider physio) Grade 3 tear - cast/ knee brace & d/w RVH	6-8 weeks
	Wrist	DTG for 4-6 weeks Futuro splint for 2 weeks then DTG	6-8 weeks
Volar Plate Injuries	Fingers	Dorsal Blocking Splints/Neighbour strapping for 3 weeks	6 weeks
Mallet finger	Fingers	Mallet splint, review clinic	6 weeks
UCL Sprains		Thumb spica. Review clinic(2 weeks) If opening, to plastics ASAP	2-4 weeks
Tenosynovitis		Futuro/ SAPOP (2 wks) +/- NSAIDS	2-6 weeks

FALLS (SEE ALSO FITS, FAINTS AND FUNNY TURNS)

It is negligent to ignore unexplained or recurrent falls!

One third of elderly patients who present to the Emergency Department after a fall have an underlying cause for it (usually gait disturbance, visual impairment or cardiovascular disorder including drug effects). All patients aged 65+ who have fallen should be screened for *unexplained or recurrent falls* by taking a careful history of the event. NICE Falls: assessment and prevention of falls in older people 2013 gives further advice.

Patients with unexplained or recurrent falls who are fit for discharge must have:

- CVS and CNS examination
- a sight test(fields and acuity)
- a gait assessment (in hours this is carried out by physio, other times doctor & nurse. Don't forget Parkinson's disease!)
- an ECG, + BP erect and supine, interpreted in conjunction with their full medication list.

They can be followed up in community by the GP or community rehab team.

HIP FRACTURES

Patients with possible hip fractures are usually managed through minors. They need timely assessment to provide adequate pain relief as soon as they arrive in hospital – consider morphine 5-10mg IV given in aliquots. Reassess pain 30 mins after administration of initial analgesia.

Femoral nerve block is a useful adjunct to pain relief but should only be performed if competent.

Typically there is a history of fall with a shortened, rotated e.g. Check neurovascular status of limb. Do not forget to assess why the patient fell – this often includes ECG, FBC / U+E and other investigations as clinically indicated.

Once diagnosed, liaise with orthopaedic SHO in RVH to arrange transfer of the patient to RVH. Antrim Hospital does not have fracture beds and patients should not be boarded in Antrim awaiting a fracture bed. Treat and stabilise any life threatening medical conditions prior to transfer.

Figure 1: Types of hip fracture (Parker M & Johansen A, 2006)[259,270]

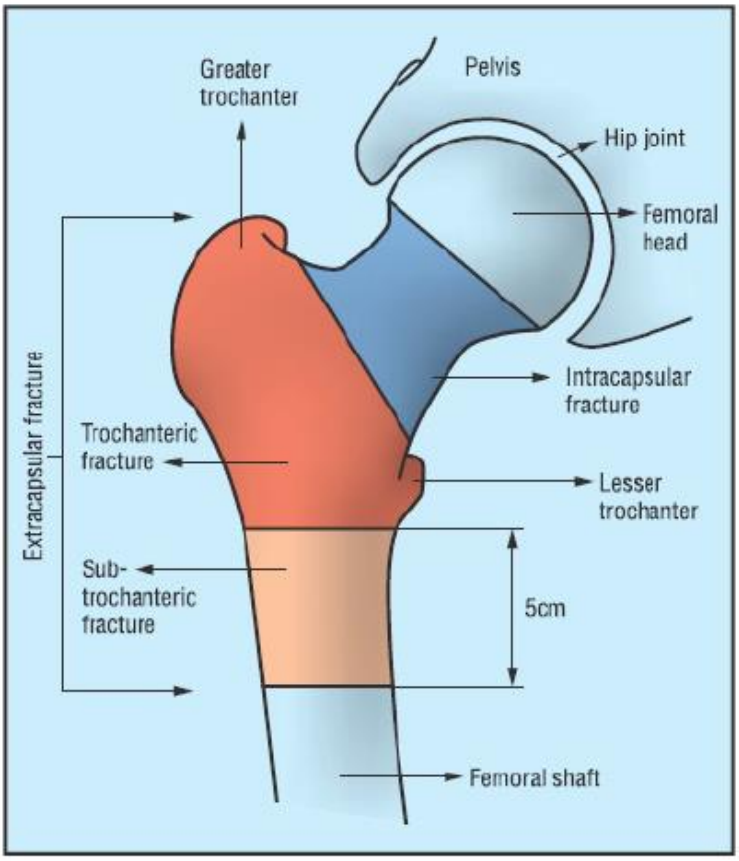

Classification of hip fractures. Fractures in the blue area are intracapsular and those in the red and orange areas are extracapsular